

Fully Digital Workflow for an Implant Retained Overdenture by Digital Smile Project to Guided Surgery and Prosthetic Rehabilitation

Luca Lavorgna, DDS¹, Tommaso Vitali, DDS², Iliaria Caviglioli DDS³, Luca Ortensi, DDS.⁴

¹Private Practice, Telese, Italy

²Private Practice, Castiglione del Lago, Italy

³Private Practice, Galliate, Italy

⁴Adjunct Professor, Department of Prosthodontics, University of Catania, Catania, Italy
Corresponding Author: Dr. Luca Ortensi, Via De Gombruti, 5, 40123, Bologna, Italy

Abstract: *The development of digital technologies in dentistry has changed the therapeutic approach in edentulous patients both in the preliminary stages of clinical case studies and when supporting the actual surgical and manufacture phases. The goals of the digital workflow are to reduce the number of patient appointments and to improve the predictability of treatment outcome. A thorough description of a complex clinical case analyzes how these new digital technologies are used in every step of the surgical and prosthetic therapy to perform the reconstruction of a bar retained overdenture.*

1. Introduction

In recent years, modern prosthetic dentistry has been making use of digital technologies to support both the diagnostic and therapeutic stages of patient rehabilitation.¹⁻⁴ Traditional removable and implant-supported dentures have also benefited from these innovations and have been further digitally developed both in the virtual planning of clinical cases and as support during the actual manufacture phase.^{5,6} The purpose of digital manufacture of implant retained overdentures is to reduce the number of patient appointments and to improve the predictability of treatment outcome.^{7,8} In a previous article the authors described the digital flow procedure for making removable dentures using a specific new software called the Digital Smile System[®] (DSS) consisting of tools and a data library of natural and artificial teeth used in interdisciplinary dentistry to improve diagnostic vision, develop communication/information, and to enhance predictability throughout the course of treatment (restorative, surgical, and prosthetic).⁹ In the procedure described, the implant positioning, although prosthetically guided, involves “free hand” surgery. The use of properly planned guided surgery, based on the anatomical situation and of the chosen prosthesis, it is a now consolidated operative criteria in clinical practice.^{10,11} The aim of this clinical report is to describe the application of these digital technology advancements in overdenture implant rehabilitation through the description of a complex clinical case, where guided-implant surgery becomes an integral part of the fully digital workflow.

2. Clinical Report

A 67-year-old female patient came to the dental office complaining of reduced chewing ability and loss of retention of her upper removable complete denture in the oral cavity. She furthermore asked to improve the appearance of her smile and face, complaining that she was dissatisfied with

the color and visibility of her teeth which, even when facial mimicry was more accentuated, were barely noticeable and featured unnatural slanted planes. The medical history showed no disease incompatible with dental therapy and an overall good state of health: the patient was classified as ASA1.

The esthetic analysis of the facial appearance showed a reduction of the vertical dimension of occlusion with an increase in perioral wrinkles. Furthermore, the musculature of the cheeks was unsupported by the old prosthesis, and the entire face had visibly lost tone (Fig.1). The patient exhibited an unattractive, slanted smile with an unbalanced look: the occlusal plan appears crooked and the interincisal line does not correspond with midline of the face.

The clinical intraoral analysis showed that the upper denture was unsatisfactory because of an inadequate extension of the prosthetic bodies, incorrect occlusal contacts, and an inadequate intermaxillary relationship. In the lower arch, there was a recently-made fixed prosthesis.

During the visit, the patient underwent a lateral radiographic exam. The radiographic examination made it possible to study the hard and soft tissues of the patient's face, and safely allows recognition of high occlusal risk brachyfacial patients, providing prognostic information for treatment planning purposes.¹² Facial and intraoral photographs were taken as an essential aid for completing the treatment plan. In general, facial photos enable further diagnostic assessments regarding the overall esthetics of the face and the physiognomic traits, which are then addressed in the prosthetic therapy.¹³

At the end of the first visit, different treatment options, with their respective associated risks and benefits, were presented and discussed with the patient. The patient accepted the permanent treatment plan of an overdenture maxillary dental prosthesis implant, supported with four dental implants.

The first clinical stage of the new prosthetic therapy entails making the preliminary impressions. This is in no way a marginal step in the process as it is essential to fully record the anatomy of the endoral structures of the edentulous upper jaw. A digital impression of the edentulous upper arch (3Shape Trios, Denmark), of the pre-existing dentures and of the opposite arch were made (Fig 2).^{14,15.}

At this point two photos were taken of the patient's face according to a coded technique for the DSS software.¹⁶It is important to take photos of the face keeping the patient in a position that is stable and repeatable over time, trying not to change the enlargement ratio between shots. For this purpose the patient was invited to sit comfortably keeping her back straight while the operator used a camera set on a tripod to stabilize its position in relation to the patient being photographed. The subject had to be positioned so that her Frankfurt Plane (the line that joins the Porion and the Orbital Point) was parallel to the horizon.

The patient may wear dedicated glasses used to calibrate the digital pre-rendering software (DSS). The glasses represent a true measuring system that differentiates this software from other similar systems.¹⁷

Thanks to their shape and the presence of calibration markers used as a reference, the glasses facilitate maintenance of the perpendicular position of the patient and the camera.

The first facial photo was taken asking the patient to smile and show as many teeth as possible. The second facial photograph was taken with cheek retractors (Fig.3). The photo made it possible to correctly assess the parallelism between the bipupillary plane and the occlusal plane, as well as the consistency between the median and interincisive line. This made it possible to import the photos (JPEG format) into the DSS and to proceed with the esthetic pre-rendering of the future prosthetic therapy.

Digital pre-rendering with the DSS program consisted of creating a digital teeth arrangement with virtual artificial teeth contained in the software library. The teeth were chosen according to esthetic and functional parameters¹⁸ and could be replaced with others of different shapes or color. If necessary the anterior and posterior teeth were positioned using the old denture as a guide. In this way the patient could see the possible esthetic end result and participate in the therapeutic project together with the entire dental team (Fig.4).

Once the virtual teeth arrangement was obtained - and approved by the patient - the file containing the patient's information, the photographic alignments, the libraries chosen, and the work process was transferred to the dental technician's laboratory where the file was imported into a 3D software program (Exocad® software, Exocad GmbH). The information file exported from the DSS consisted of a PDF format and single photographs of the patient's face with a customized two dimensional (2D) virtual smile design.

The files from DSS were then superimposed onto scanned images of denture and edentulous upper jaw.¹⁹The dental technician used the outline of the virtual smile obtained to place a tooth from the library or to create customized teeth with tools from Freeform (Exocad® software, Exocad GmbH) to convert the virtual 2D teeth arrangement into a 3D teeth arrangement (Fig 5).²⁰

At the end of this work stage, a file from Exocad was converted into a specific file for a 3D printer (SLA 3D, Form 2, Formlabs Inc.)and a prototype of the digital work was made with a dedicated resin (C&B, A3.5, NextDent B.V.) (Fig 6).²¹

The prototype was tried in the mouth checking the intraoral adaptation, the centric relation, and the esthetics of the smile and face (Fig.7). The clinician could make changes if necessary.

Subsequently the prototype is used as a radiological stentwith which the CBCT is done, using a dedicated device (Evobitewith 3D marker, 3diemme, Italy)which was adapted to the item with radiotransparent silicone (Fig. 8).

The Dicomdata resulting from the X-ray and the STL files relative to the anatomical and prosthetic parts obtained from the intraoral scan are imported in a specific implant planning software (Realign 5.0, 3 DIEMME, Italy)where, thanks to adedicatedalgorhythm, are overlapped using a replicable and controlled procedure (Fig. 9).Through use of the implant line database used (Thommen Medical AG, Grenchen, Switzerland) the number and position of the implant screws to be inserted via guided-surgery are planned (Fig. 10).

After careful functional and esthetic evaluation and final verification, the prosthetic-driven plan was approved, and a stereolithographic surgical template was made using a newer rapid prototyping technology (New Ancorvis, Bargellino, Italy) (Fig. 11). Subsequently four prosthetic-driven implants with a diameter of 4.0 mm and a length of 9.5 mm (SPI ® CONTACT RC INICELL®, ThommenMedicalAG) were placed, with a dedicated dedicated bur kit (Thommen Medical Guided Surgery Kit), in the upper jaw, taking into account the bone quality and quantity, soft-tissue thickness, anatomical landmarks, and the type, volume and shape of the final restoration.

Healing abutments were positioned directly onto the implant heads and the old denture was realigned with a temporary soft material (Coe Soft (CS) GC America Inc.) (Fig. 12).

After four weeks,²² the final digital impression (Trios 3Shape) of the upper arch was made of the implant scan bodies previously screwed into the fixture with a set torque. In addition, the final volume of the clinicized prototype were also reacquired so as to digitally superimpose the images onto each other. Superimposing of various digital files has proven to be a reliable procedure in digital workflows.²³

Using a dedicated tool of the 3D software (Exocad® software, Exocad GmbH), the project was executed to create the upper retentive bar, using fixture scan transparencies to assess the available spaces and the position of the teeth in

relation to their analogues, and to identify the type of prosthetic structure and anchorage. The structure project was sent to the milling center (New Ancorvis): indications were given regarding the retentive system anchorage areas, the use of dedicated threading, the type of metal, and the execution technique (CAD/CAM technology).

After being checked in the dental technician's lab, the item was sent to the dentist to clinically test the structure, in order to verify its precision and passivity. The dentist took a pick-up impression of the bar so that it was possible to make a master model stone to finalize the prosthesis.

The process later continued with further polishing and shining of the bar and the digital acquisition using a scanner. The dental technician digitally designed the counter-bar, always checking the available spaces, using final volume superimposition and inserting retentive pins in the project for the mechanical tightness of the teeth. It was made using laser-melting technology that made it possible to obtain an accurate item to which the acrylic resin adhered tightly thanks to the presence of a retentive surface.²⁴

It was then time for the complete application of the teeth onto the counter-bar, using the clinicized prototype as a fitting plane. The artificial teeth and the metal structure were joined using a small amount of wax.

The prosthesis was finalized using a resin injection muffle system (Vertysystem^R, a-gree srl) that transformed the wax into resin with a codified protocol.²⁵⁻²⁶ The overdenture and the finished and perfectly polished retention structure were sent to the dental office.

The bar was then inserted into the oral cavity by the clinician and tightened to the implant fixtures with a preset torque (Fig 13). The dentist had to check that there were no areas where the soft tissues were compressed and that there was room for the use of dental devices: interdental brushes and flosses.

Once the prosthetic therapy was completed, the patient's face had improved greatly from an esthetic viewpoint. The soft tissues of the face appeared firm and toned. A reduction could be seen in the naso-labial folds and perilabial wrinkles, both frontally and laterally. The vertical dimension, which had been slightly increased, appeared adequate and well tolerated esthetically. During phonation and smiling dynamics the patient displayed natural looking teeth that were perfectly integrated with her face (Fig.14).

3. Discussion

In prosthetic therapy, for both fixed and removable prostheses, communication with the patient is a vital part of the treatment. Effective digital previsualization is the ideal way to explain esthetic changes to a patient and to receive their approval. Until now, many digital previsualization methods have been used in dentistry solely for this purpose.

In this article the Digital Smile approach was introduced in a complex digital workflow. DSS not only allowed the patient to see her future appearance, but it also enabled production

of a prototype (Patent Pending Workflow, Just Digital, Italy) for the functional check of the digital project carried out. The fact that the patient can see the possible future esthetic results through digital rendering, including the possibility of changes if desired, reduces overall clinical practice time. Additionally, the construction of a prototype, based on the virtual assembly, minimizes the number of errors in the manufacture of the final product and becomes a fundamental instrument for prosthetic-driven surgery.

Use of the prototype as a radiological stent during the examination of the CBCT, and its transformation into a surgery-driven guide make it possible to position implants according to the digital study done with DSS and approved by the patient.

Some phases of the described workflow require a learning curve by the clinical operator and technician. For example, the photos taken by the clinician for the DSS, must be taken in the exact manner as previously described to facilitate the superimposing of the photo of the patient's face, with the scan of the model and the old denture. Another important stage is that in which the teeth from the databank of the 3D software are matched with the outlines obtained by digital previsualization with DSS. In this case, if the matching is not precise, the prototype will not correspond perfectly with that approved by the patient.

4. Conclusions

The use of digital technologies is now vastly widespread in the field of dentistry and, in particular, in prosthetic therapy. In removable, traditional, and implant-support prosthetic therapy, digital technology can play an essential role. The clinical case described was almost entirely resolved with an innovative digital workflow, both from a clinical and technical viewpoint. In particular, guided-surgery has come into the digital workflow through a simplified approach that is closely dependent on the esthetic and functional aspects of the patient. The human component is still fundamental and not all stages can be carried out digitally. However, it is expected that technical development will rapidly lead to more and more digitalized therapies with an increase in the end quality of the therapy and less conditioned by the skills of the individual operator.

5. Acknowledgments

The authors thank Mr. Gianni Ortensi, CDT, Mr. Marco Ortensi, CDT, who made the bar retained overdenture.

References

- [1] Coachman, C., & Calamita, M. A. (2014). VIRTUAL Esthetic Smile Design. *Journal of Cosmetic Dentistry*, 29(4).
- [2] Ortensi, L., Stefani, R., Caviggioli, I., Molinelli, F. (2011). La prima visita in odontoiatria protesica: aspetti innovativi. *Il Dentista Moderno*.
- [3] Zimmermann, M., & Mehl, A. (2015). Virtual smile design systems: a current review. *International journal of computerized dentistry*, 18(4), 303-317.

- [4] Coachman, C. (2012). Calamita M. *Digital Smile Design: a tool for treatment planning and communication in esthetic dentistry. QDT.*
- [5] Goodacre, C. J., Garbacea, A., Naylor, W. P., Daher, T., Marchack, C. B., & Lowry, J. (2012). CAD/CAM fabricated complete dentures: concepts and clinical methods of obtaining required morphological data. *The Journal of prosthetic dentistry, 107*(1), 34-46.
- [6] Infante, L., Yilmaz, B., McGlumphy, E., & Finger, I. (2014). Fabricating complete dentures with CAD/CAM technology. *The Journal of prosthetic dentistry, 111*(5), 351-355.
- [7] Kattadiyil, M. T., Jekki, R., Goodacre, C. J., & Baba, N. Z. (2015). Comparison of treatment outcomes in digital and conventional complete removable dental prosthesis fabrications in a predoctoral setting. *The Journal of prosthetic dentistry, 114*(6), 818-825.
- [8] Rossi M, Molinelli F, Caviggioli I.(2015). Latest trends in prosthetics - Total maxillary rehabilitation with a Toronto Bridge using digital technologies. CAD/CAM. *International magazine of digitaldentistry*;1:28-31.
- [9] Ortensi L, Stefani R, Lavorgna L, Caviggioli I, Vitali T. (2018). A Digital Workflow for an Implant Retained over Denture: A New Approach. *Biomed J Sci&Tech Res* 6(5).
- [10] Vercruyssen, M., Laleman, I., Jacobs, R., & Quirynen, M. (2015). Computer-supported implant planning and guided surgery: a narrative review. *Clinical oral implants research, 26*, 69-76.
- [11] Tallarico, M., Esposito, M., Xhanari, E., Caneva, M., & Meloni, S. M. (2018). Computer-guided vs freehand placement of immediately loaded dental implants: 5-year post-loading results of a randomised controlled trial. *European journal of oral implantology, 11*(2).
- [12] Ortensi, L., Martini, M., Montanari, M., & Galassini, G. (2017). A Simplified Method to Identify Patient Face Type for a Prosthodontic Treatment Plan. *J Dent Health Oral Disord Ther, 8*(4), 00291.
- [13] McLaren E.A., Terry D. (2001). Photography in dentistry. *J Calif Dental Ass*;29.10:735-742.
- [14] Kim, J. E., Amelya, A., Shin, Y., & Shim, J. S. (2017). Accuracy of intraoral digital impressions using an artificial landmark. *The Journal of prosthetic dentistry, 117*(6), 755-761.
- [15] Kim, J. E., Kim, N. H., & Shim, J. S. (2017). Fabrication of a complete, removable dental prosthesis from a digital intraoral impression for a patient with an excessively tight reconstructed lip after oral cancer treatment: A clinical report. *The Journal of prosthetic dentistry, 117*(2), 205-208.
- [16] Stefani R, Caviggioli I, Molinelli F, Ortensi L. (2012). L'impiego delle tecnologie digitali nella diagnosi protesica e nella realizzazione della protesi. *Il DentistaModerno.*
- [17] Jokstad, A. (2017). Computer-assisted technologies used in oral rehabilitation and the clinical documentation of alleged advantages—a systematic review. *Journal of oral rehabilitation, 44*(4), 261-290.
- [18] Lombardi, R. E. (1977). Factors mediating against excellence in dental esthetics. *Journal of Prosthetic Dentistry, 38*(3), 243-248.
- [19] Joda, T., Brägger, U., & Gallucci, G. (2015). Systematic literature review of digital three-dimensional superimposition techniques to create virtual dental patients. *International journal of oral & maxillofacial implants, 30*(2).
- [20] Zhang, C., Liu, T., Liao, W., Yang, T., & Jiang, L. (2017). Computer-aided design of dental inlay restoration based on dual-factor constrained deformation. *Advances in Engineering Software, 114*, 71-84.
- [21] Rengier, F., Mehndiratta, A., Von Tengg-Kobligh, H., Zechmann, C. M., Unterhinninghofen, R., Kauczor, H. U., & Giesel, F. L. (2010). 3D printing based on imaging data: review of medical applications. *International journal of computer assisted radiology and surgery, 5*(4), 335-341.
- [22] Burkhardt, M. A., Waser, J., Milleret, V., Gerber, I., Emmert, M. Y., Foolen, J., ... & Vogel, V. (2016). Synergistic interactions of blood-borne immune cells, fibroblasts and extracellular matrix drive repair in an in vitro peri-implant wound healing model. *Scientific reports, 6*, 21071.
- [23] Coachman, C., Calamita, M. A., Coachman, F. G., Coachman, R. G., & Sesma, N. (2017). Facially generated and cephalometric guided 3D digital design for complete mouth implant rehabilitation: A clinical report. *The Journal of prosthetic dentistry, 117*(5), 577-586.
- [24] Koutsoukis, T., Zinelis, S., Eliades, G., Al-Wazzan, K., Rifaiy, M. A., & Al Jabbari, Y. S. (2015). Selective Laser Melting Technique of Co-Cr Dental Alloys: A Review of Structure and Properties and Comparative Analysis with Other Available Techniques. *Journal of Prosthodontics, 24*(4), 303-312.
- [25] Goodacre, B. J., Goodacre, C. J., Baba, N. Z., & Kattadiyil, M. T. (2018). Comparison of denture tooth movement between CAD-CAM and conventional fabrication techniques. *The Journal of prosthetic dentistry, 119*(1), 108-115.
- [26] Marco, M., Giuliano, B., & Luca, O. (2016). Oral Rehabilitation with Implant-Supported Overdenture and a New Protocol for Bar Passivation. *Global Journal of Oral Science, 2*, 10-19.

Photo Captions



Figure 1: Initial state of the face: a reduction of the vertical dimension is observed with an increase in perilabial wrinkles.

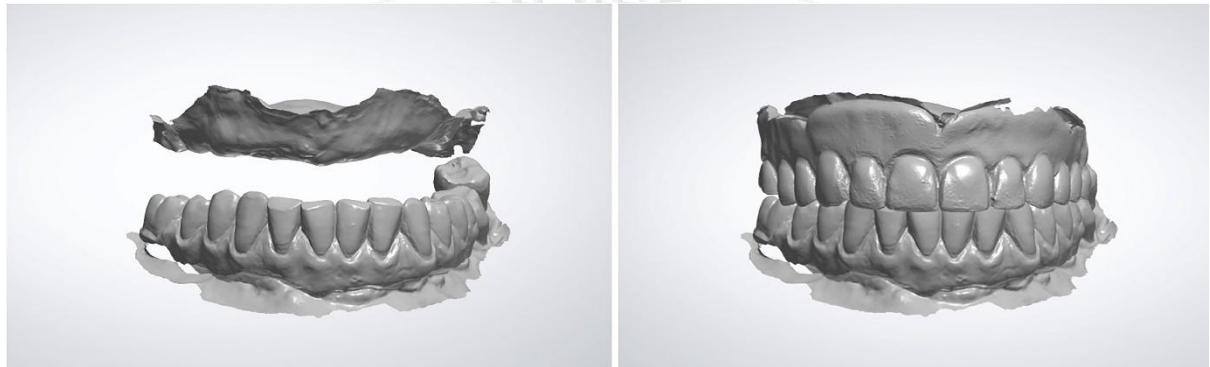


Figure 2: A digital impression was made of the edentulous upper arch, old dentures and of the opposite arch.

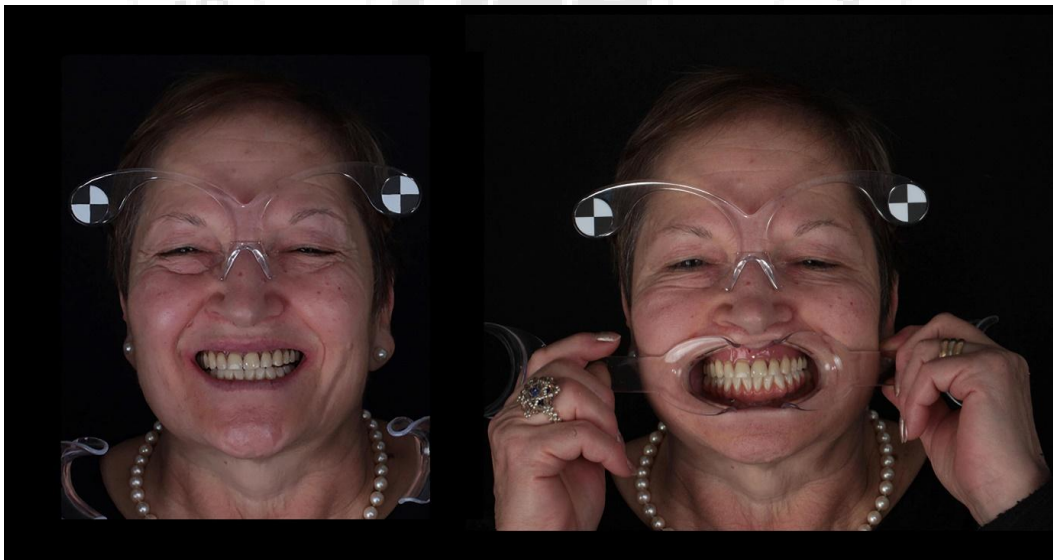

Figure 3: The first facial photo was taken asking the patient to smile and show as many teeth as possible and the second facial photograph was taken with cheek retractors

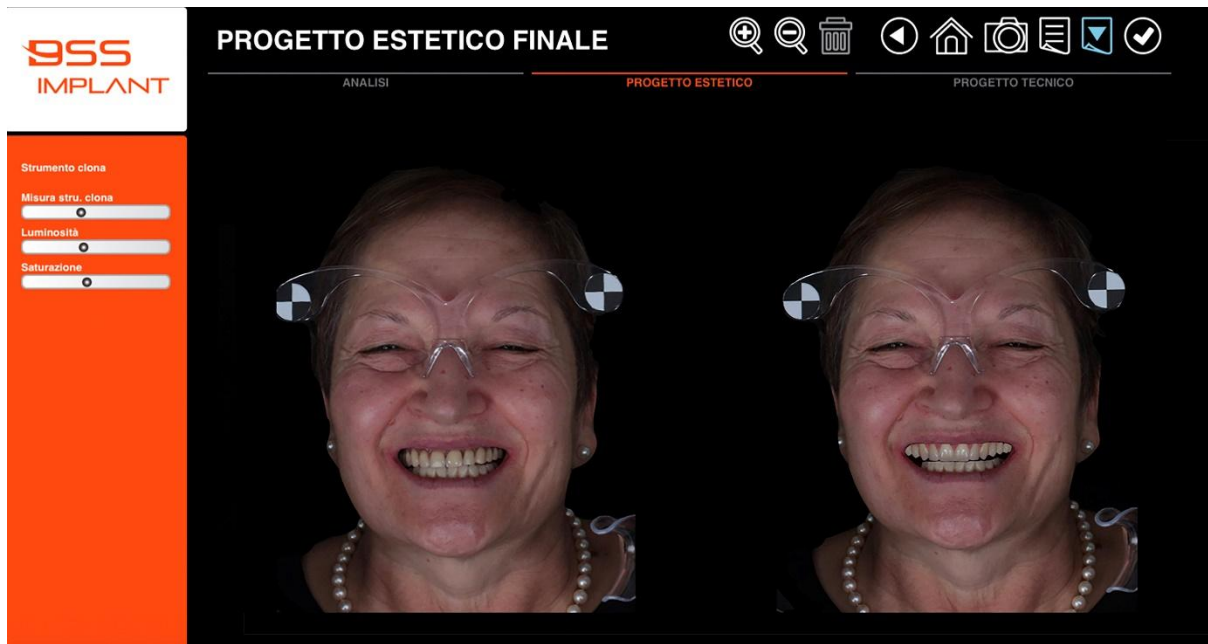

Figure 4: Patient's digital pre-rendering with the DSS software

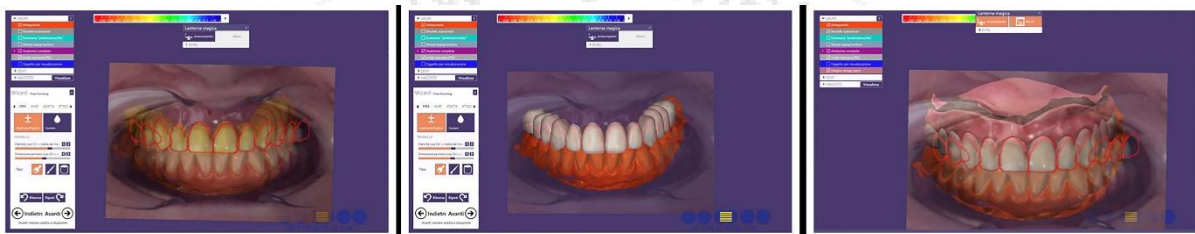


Figure 5: The dental technician used the outline of the virtual smile obtained to place a tooth from the library or to create customized teeth to convert the virtual 2D teeth arrangement into a 3D teeth arrangement

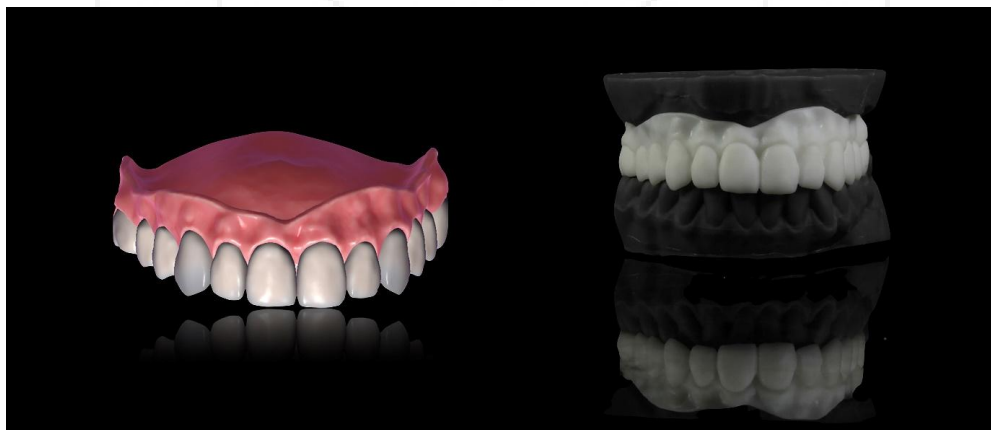

Figure 6: A prototype of the digital work was obtained with a dedicated resin



Figure 7: Face of patient with prototypes inserted into the mouth to check esthetics



Figure 8: The prototype was used as a radiological stent during the conduct of the CBCT

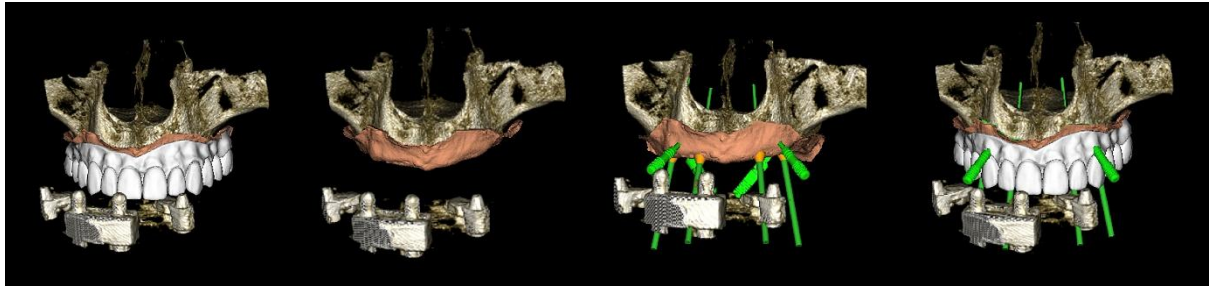


Figure 9: The Dicomdata and the STL files relative to the anatomical and prosthetic parts obtained from the intraoral scan are imported into a specific implant-planning software

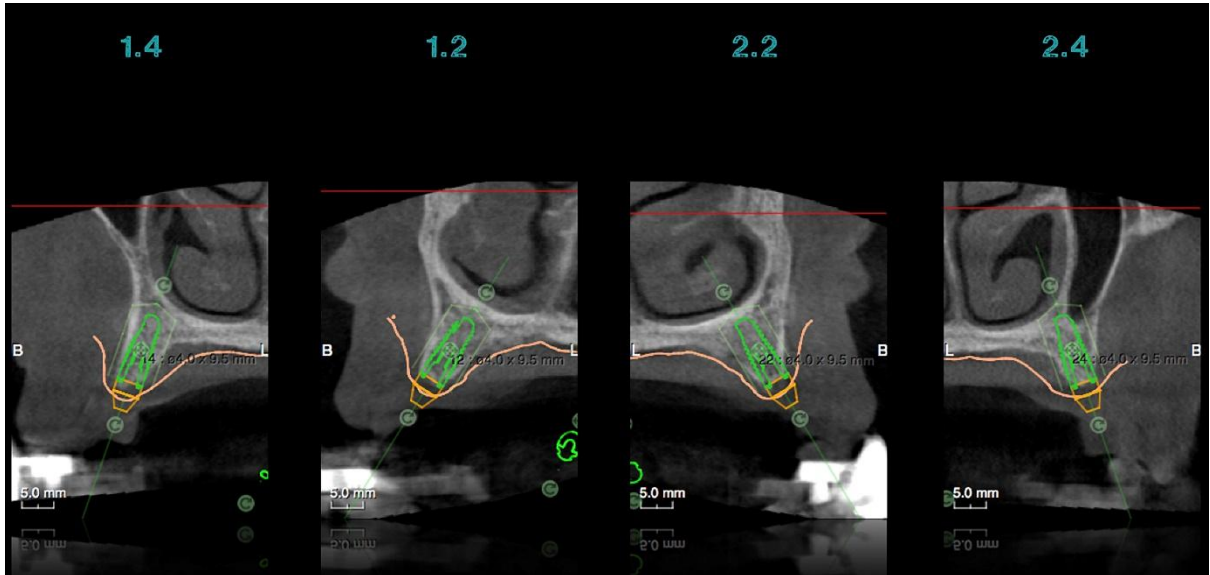


Figure 10: The number and position of the implant screws to be inserted via guided-surgery are planned through use of an implant line database

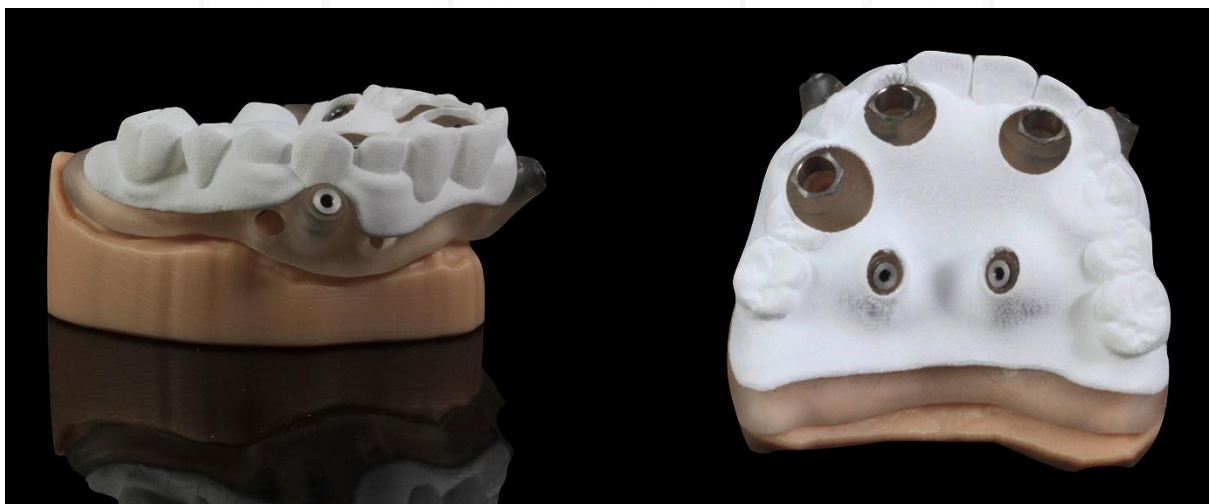

Figure 11: A stereolithographic surgical template was made with a rapid new prototyping technology.

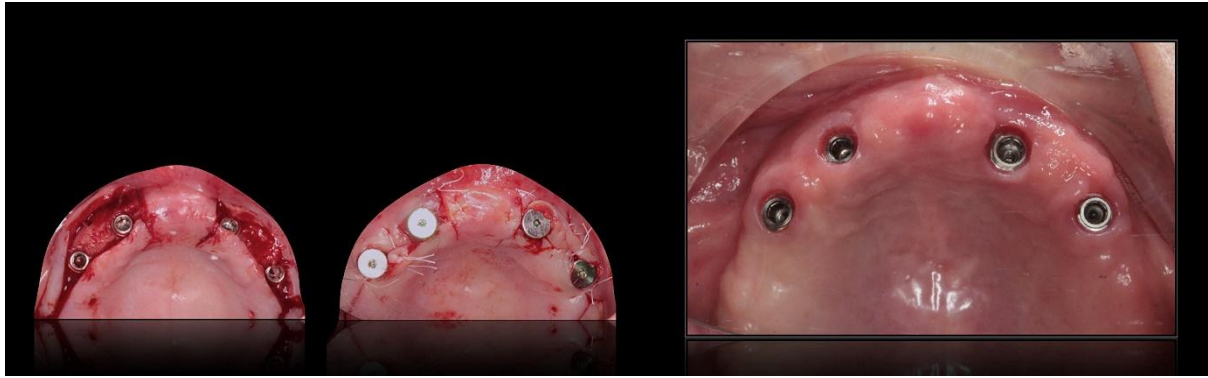


Figure 12: After the guided surgery the healing abutments were positioned directly onto the implant

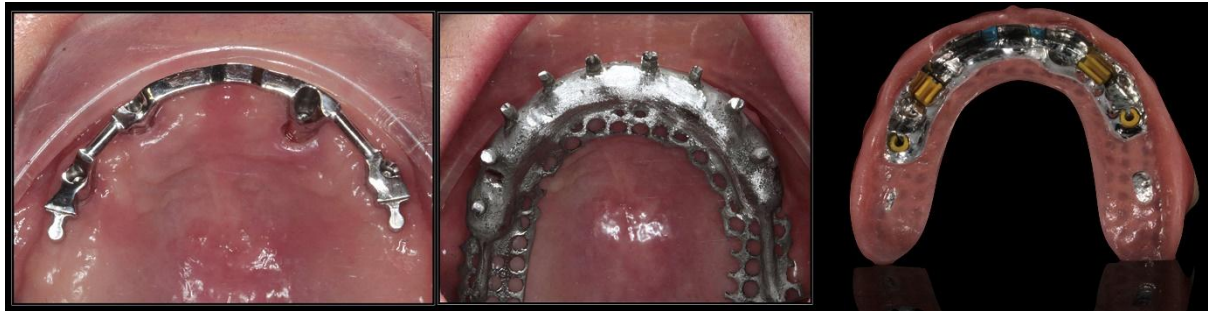

Figure 13: Bar inserted into oral cavity



Figure 14: Once the prosthetic therapy was completed, the patient's face improved greatly from an esthetic viewpoint